

ASYMPTOMATIC DYSBARIC OSTEONECROSIS IN JAPANESE DIVERS

**Masayuki Kawashima, Mahito Kawashima,
Hiroaki Tamura, Katsuhiro Takao,
Takashi Yamaguchi, Kenji Miyata**

Kawashima Orthopaedic Hospital

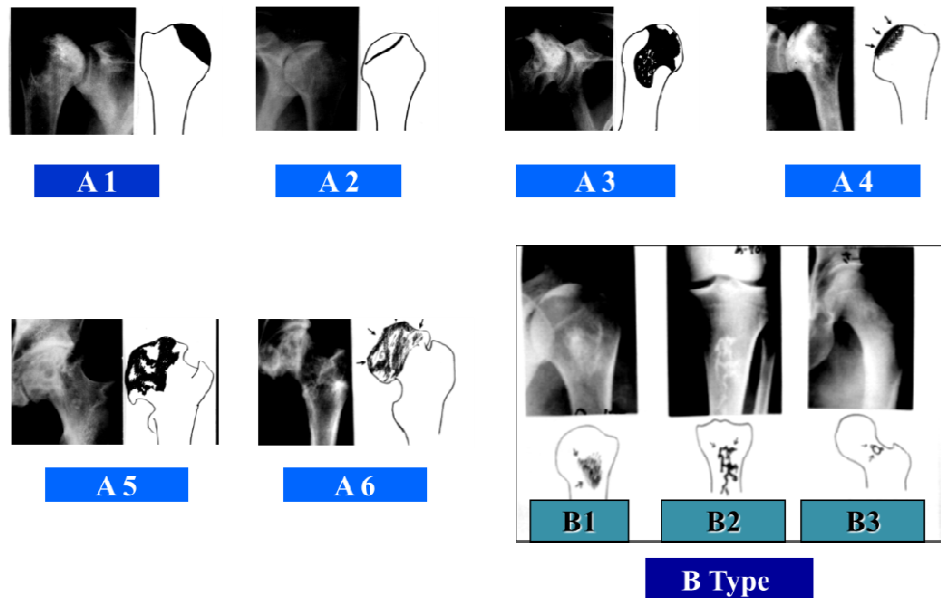
INTRODUCTION

Dysbaric osteonecrosis (DON) is a serious problem among divers. We have examined bone x-rays or magnetic resonance imaging (MRI) of divers from 1981 to 2012.

Duration	1981 March ~ 2013 January
Number of Examination	354 cases
Number of Divers	164 cases (Male:162 Female:2)

MATERIALS and METHODS

164 divers who visited our hospital to check if they had DON were examined by X-rays and/or MRI of shoulders, hip joints, and knee joints. We investigated about the existence of DON, the length of diving experience, the depth of diving, the working hours, lesion, and the type of DON. Bone lesions were classified by Ota-Matsunaga Classification which is the modified MRC of the U.K. Bone lesions in divers.



Ota-Matsunaga Classification
(Modified MRC)

RESULTS

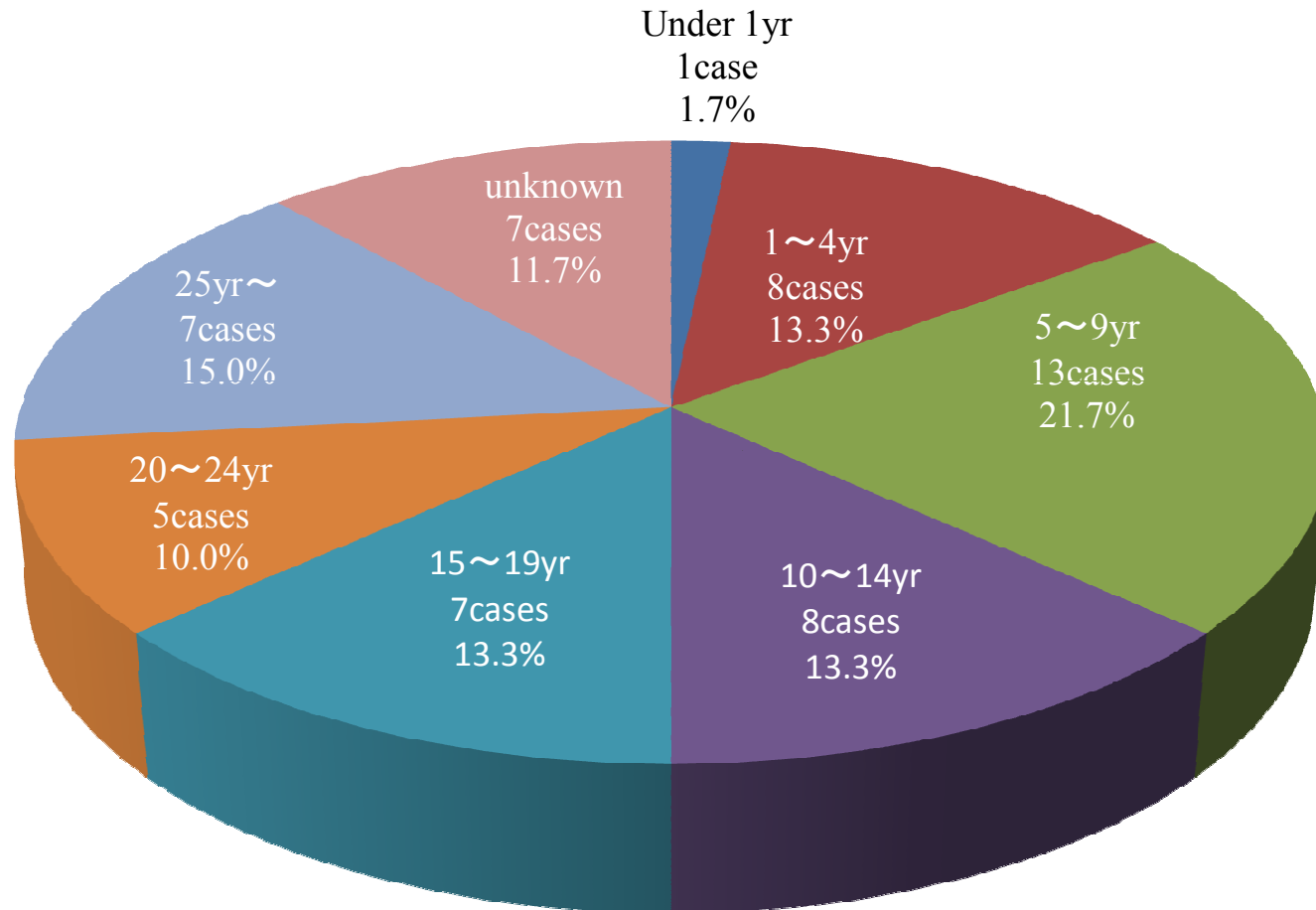
Osteonecrosis	60/164cases	36.6%
	(Male : 60	Female : 0)

Number of Bone Lesion

Number of Bone Lesion	Number of Cases	Rate
1	31	51.7%
2	12	20.0%
3	7	11.7%
4	6	10.0%
5	2	3.3%
6	2	3.3%
Total	60	100%

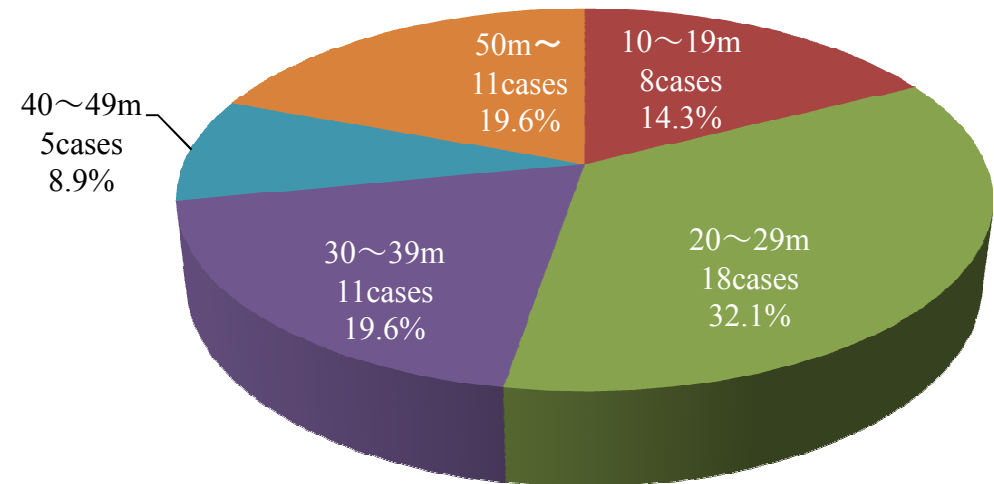
Diving Experience

(Divers with Bone Lesion)

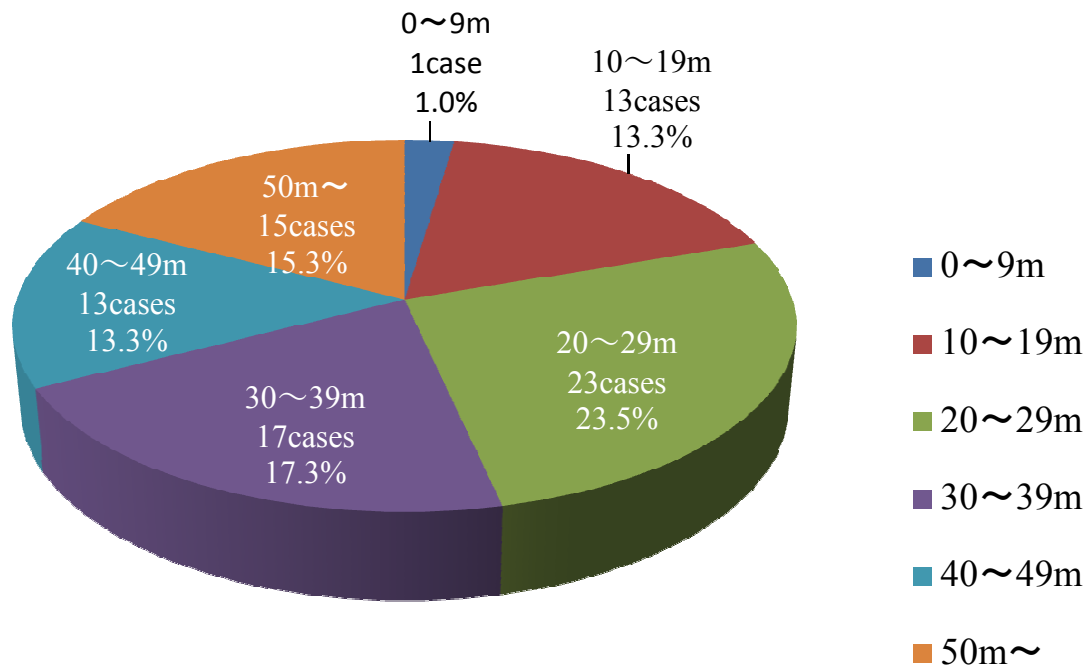


Maximum Depth of Diving & Bone Lesion

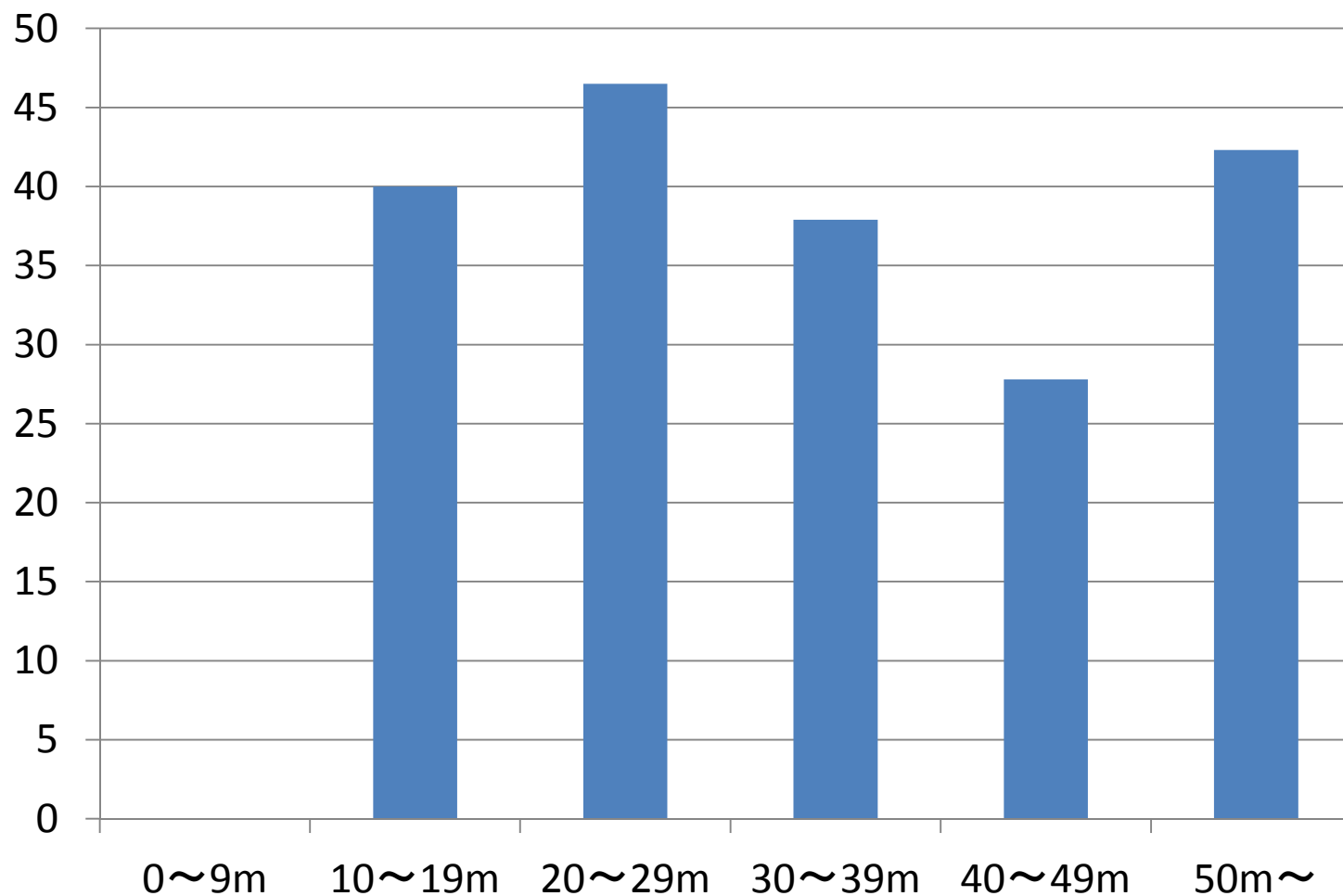
with Bone Lesion



without Bone Lesion

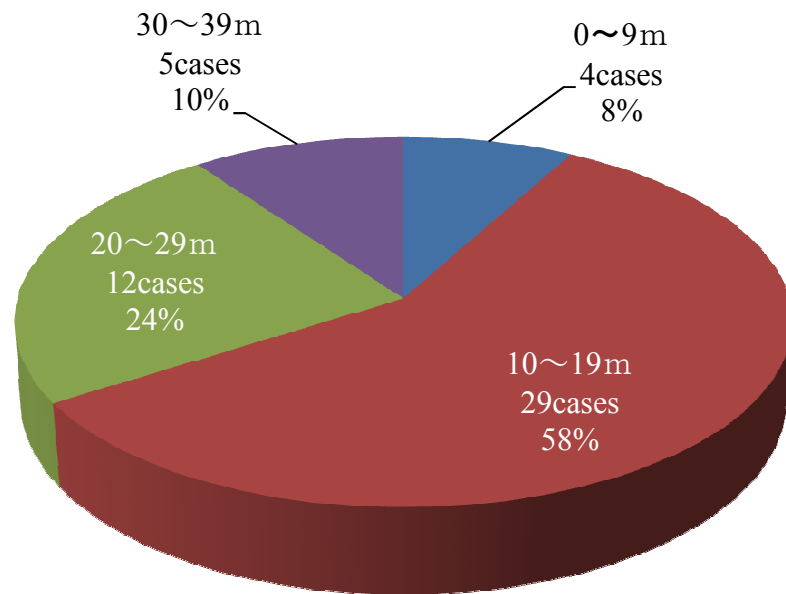


Maximum Depth of Diving & Incidence of Bone Lesion

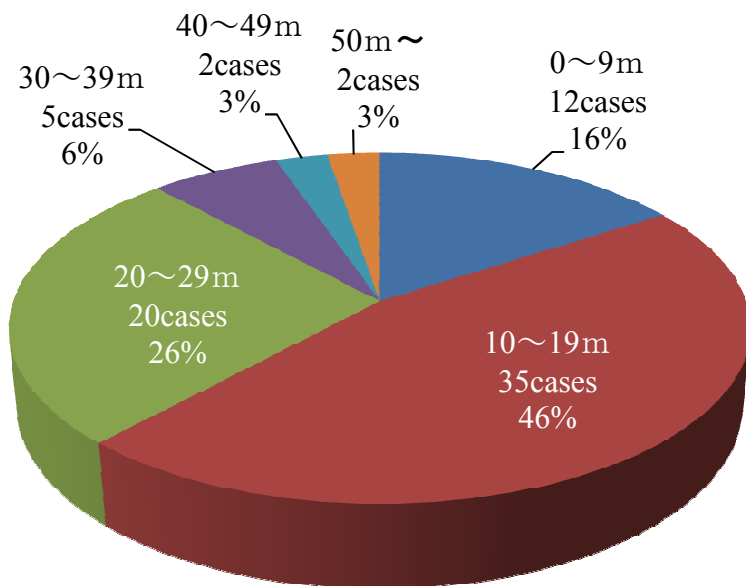


Average Depth of Diving & Bone Lesion

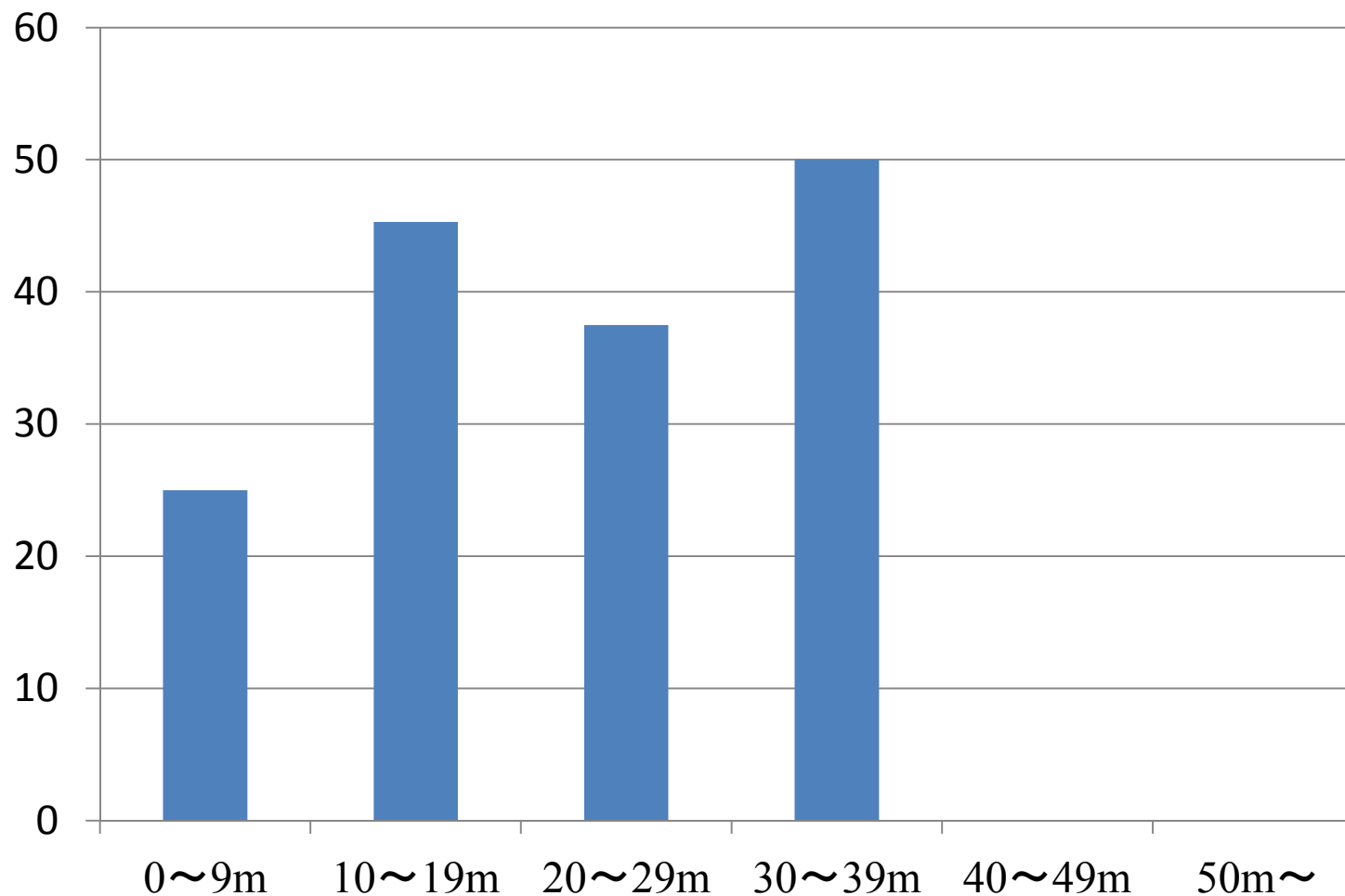
with Bone Lesion



without Bone Lesion



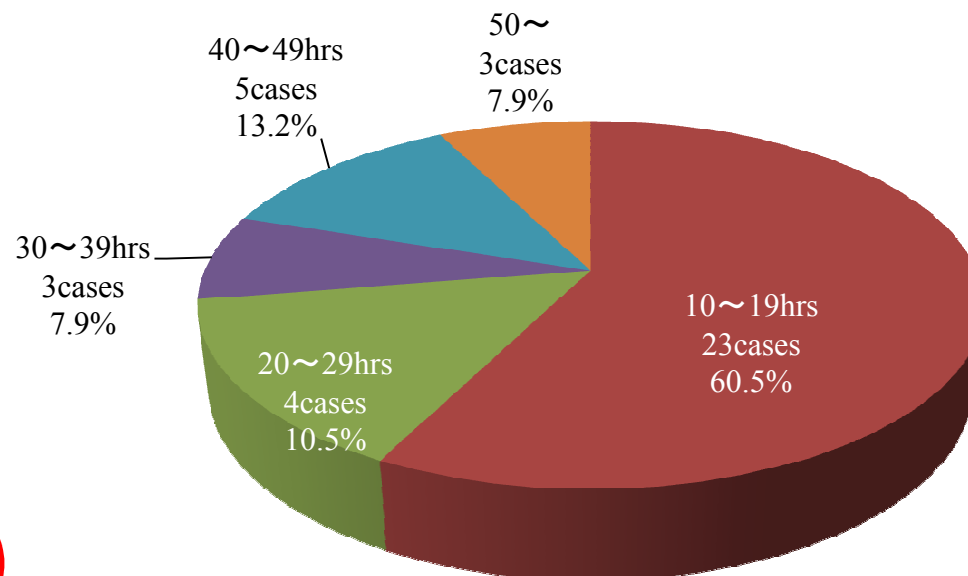
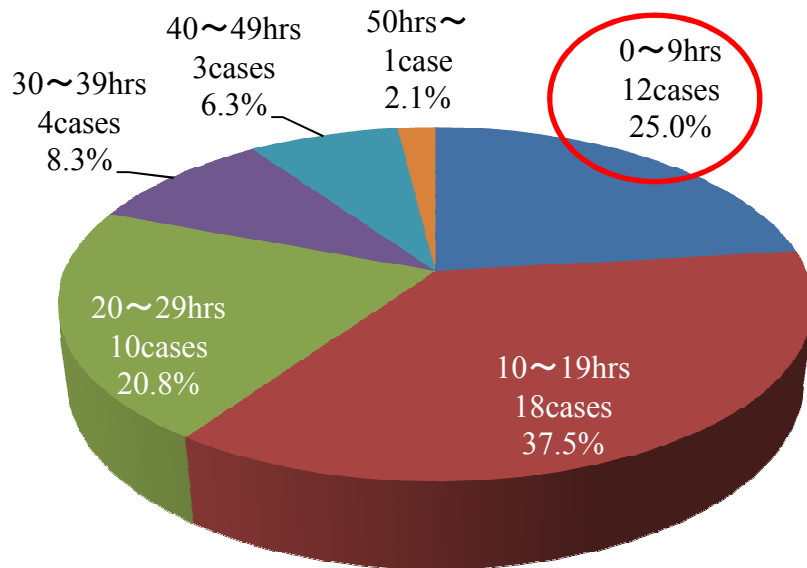
Average Depth of Diving & Incidence of Bone Lesion



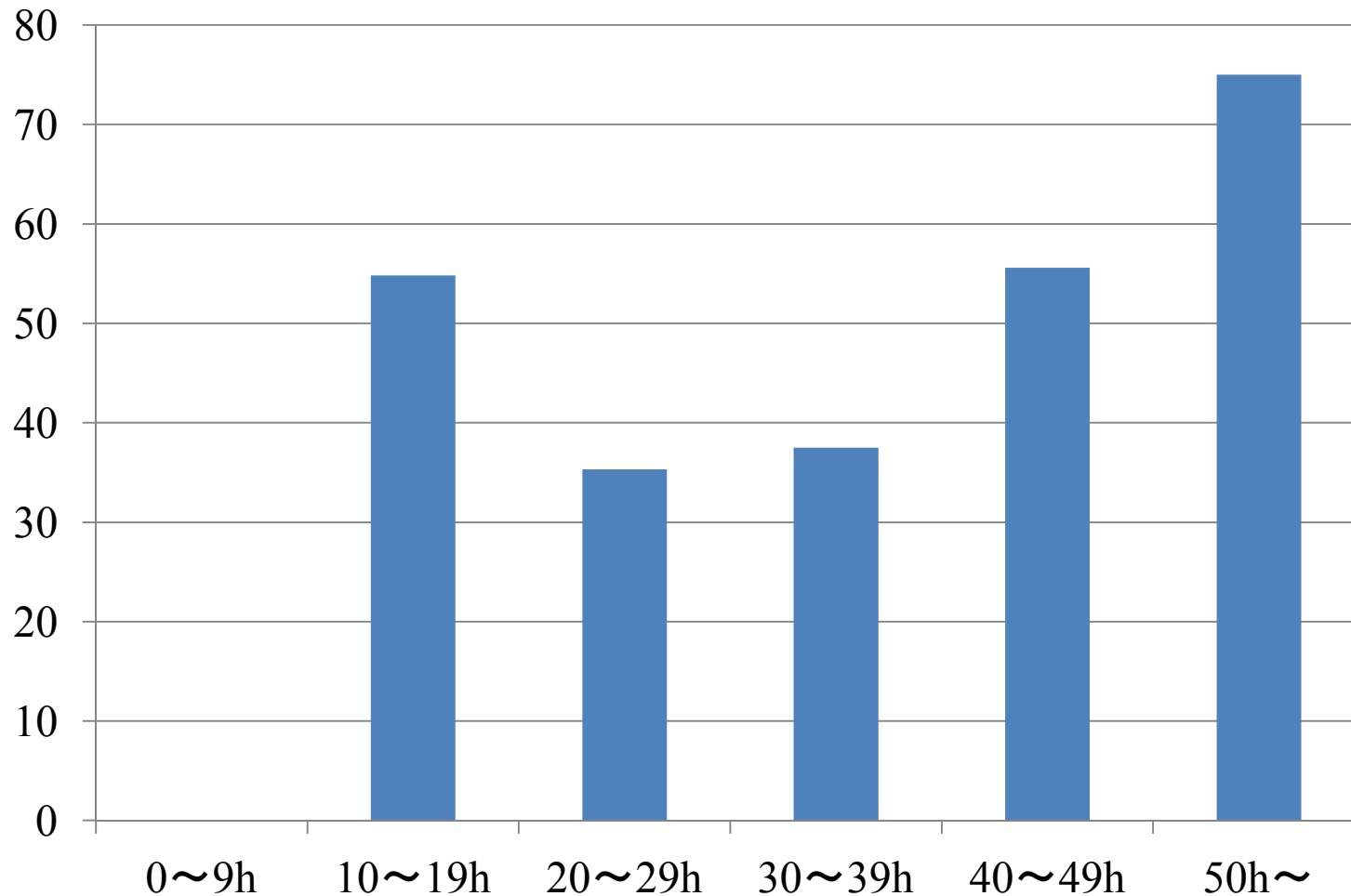
Working Hours a Week

with Bone Lesion

without Bone Lesion



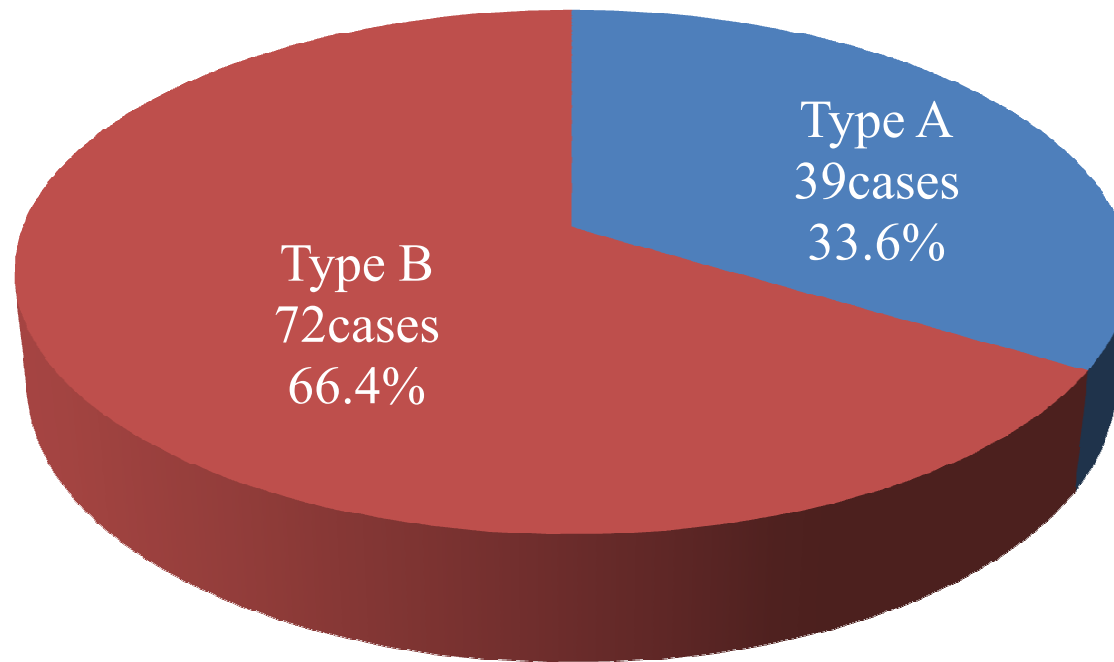
Working Hours a Week & Incidence of Bone Lesion



Site of Bone Lesion

Site of Bone Lesion	Number of Cases	Total
Humerus (Lt)	8	48
Humerus (Rt)	10	
Humerus (Both)	15	
Forearm (Lt)	0	3
Forearm (Rt)	3	
Forearm (Both)	0	
Femur (Lt)	26	58
Femur (Rt)	8	
Femur (Both)	12	
Tibia (Lt)	2	9
Tibia (Rt)	1	
Tibia (Both)	3	
Knee (Lt)	1	6
Knee (Rt)	1	
Knee (Both)	2	
Total	92	124

Type of Bone Lesion



Ota-Matsunaga Classification
(Modified MRC)

Previous History of Decompression Sickness

Bone Lesion	(+) 29cases ^(*1)	(-) 73cases ^(*1)
Bends	17cases (58.6%)	22cases (30.1%)
Spinal Cord	1case (3.4%)	1case (1.4%)
Brain	2cases (6.9%)	4cases (5.5%)
Squeeze	3cases (10.3%)	2cases (2.7%)
Osteonecrosis (THA)	1case ^(*2) (3.4%)	0case (0.0%)
Unknown	0case (0.0%)	1case (1.4%)
Total ^(*3) ^(*4)	21cases (72.4%)	25cases (34.2%)

(*1) the cases with records of previous history of decompression sickness

(*2) Osteonecrosis at both of shoulders was found in this case at the examination.

(*3) Some cases have the plural previous history.

(*4) χ^2 test $p < 0.05$

CONCLUSION

- 1) Osteonecrosis was found in 36.6% cases of asymptomatic divers.
- 2) Osteonecrosis was not found in divers who work less than 10 hours a week.
- 3) Osteonecrosis was more in proximal site of limbs.
- 4) It was found that more than 70% cases of divers with osteonecrosis had previous history of decompression sickness.
- 5) Even if divers don't have any symptoms, they should receive regular radiologic examinations.